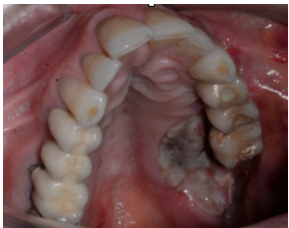

## BlueM, for the protection of injured periodontal tissue



*BlueM oral gel on a acute necrotizing deep ulcer*

October 2016 • Curitiba Brazil

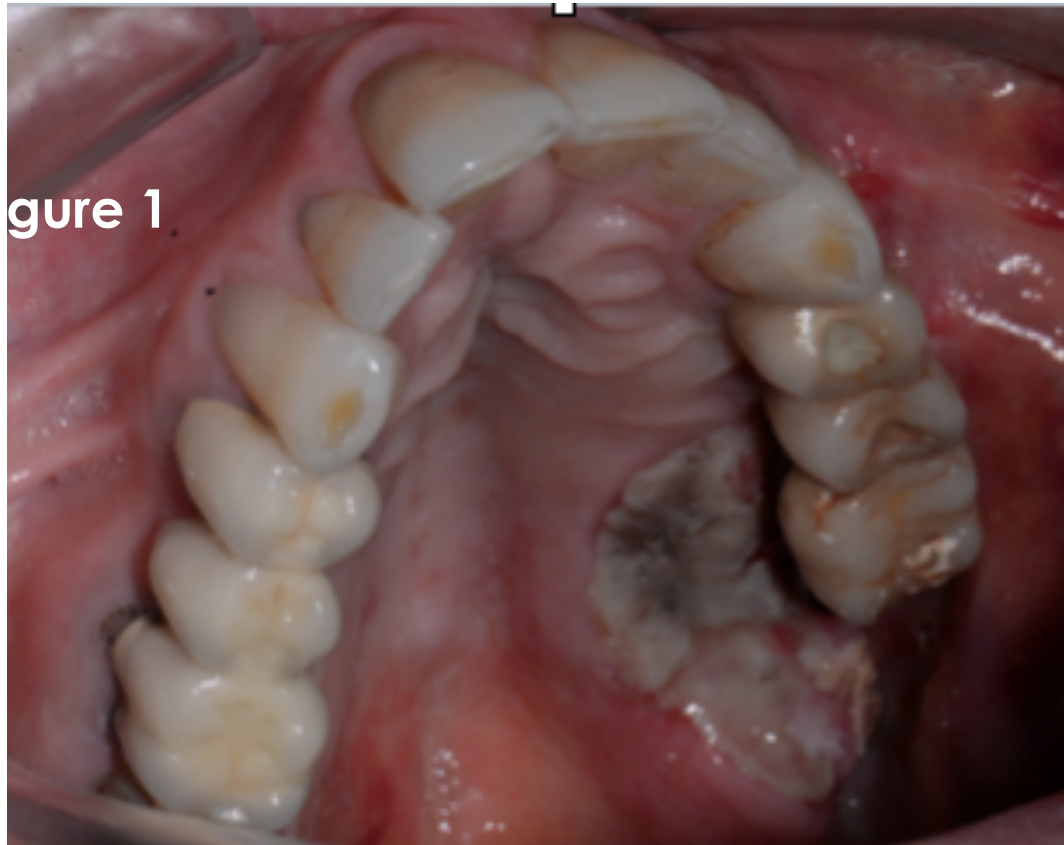## BlueM, for the protection of injured periodontal tissue

Prof. Dr. Me. ANDRÉ LUIS ZÉTOLA , Curitiba Brazil.  
Oral and maxillofacial surgeon specialised in maxillofacial trauma.



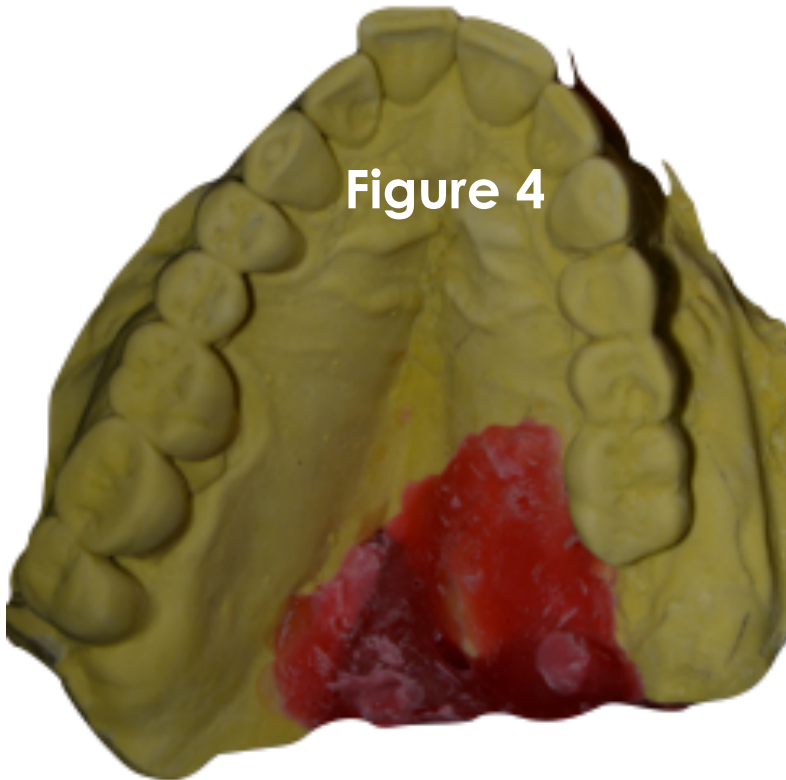
- Dr. in Implantology, UFSC (Federal University of Santa Catarina);
- Master in Head & Neck surgery, Heliópolis Institute São Paulo;
- Specialist Maxillo-Facial Surgery, UERJ (Universidade do Estado do Rio de Janeiro);
- Post Graduate Buco Maxillo Facial & Implantology Surgery, Northwestern University Chicago;
- Former President Brazilian Academy of Osseointegration ABROSS;
- Coordinator specialization course in implantology of SOEPAR( Association of Dentology Paraná);
- His experience in dentistry has emphasis on orthodontics and operates mainly in the following themes: desmoplastic fibroma maxillofacial surgery, traumatology.

BlueM, for the protection of injured periodontal tissue  
A acute necrotizing deep ulcer.



BlueM, for the protection of injured periodontal tissue

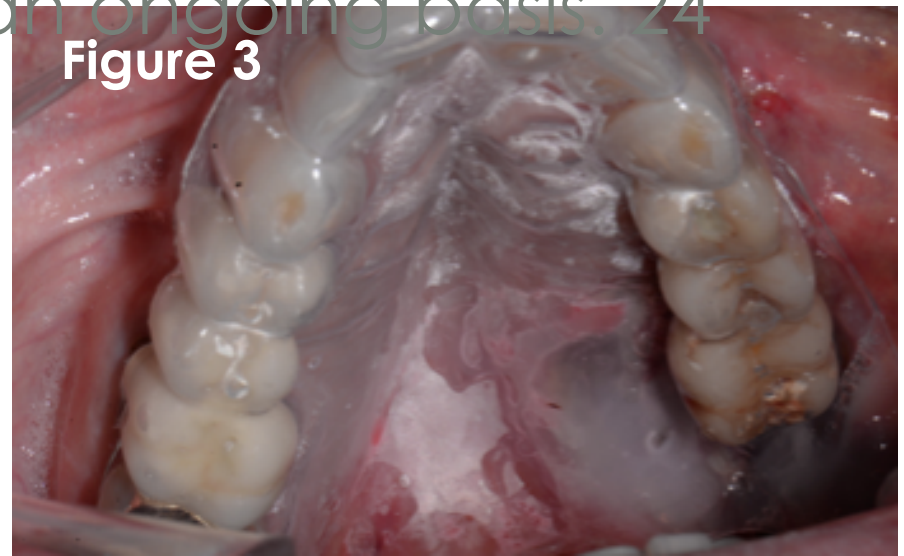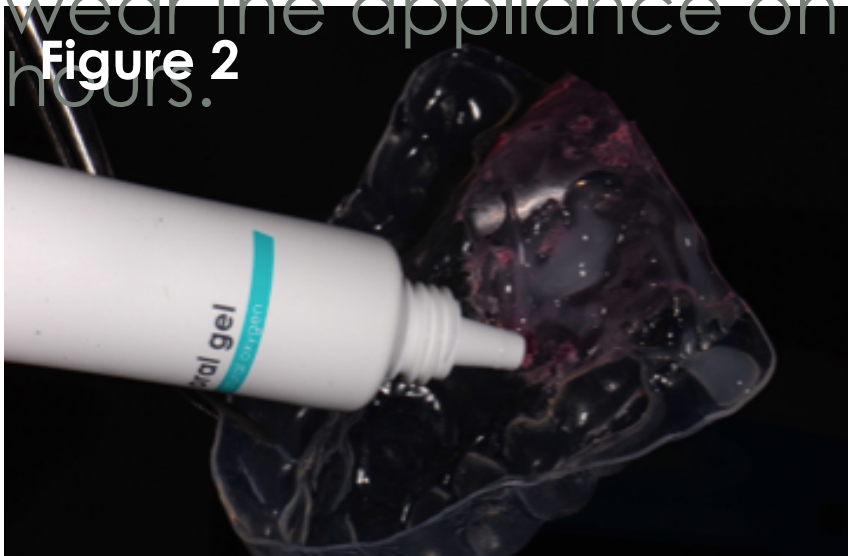**Figure 4**



Impression

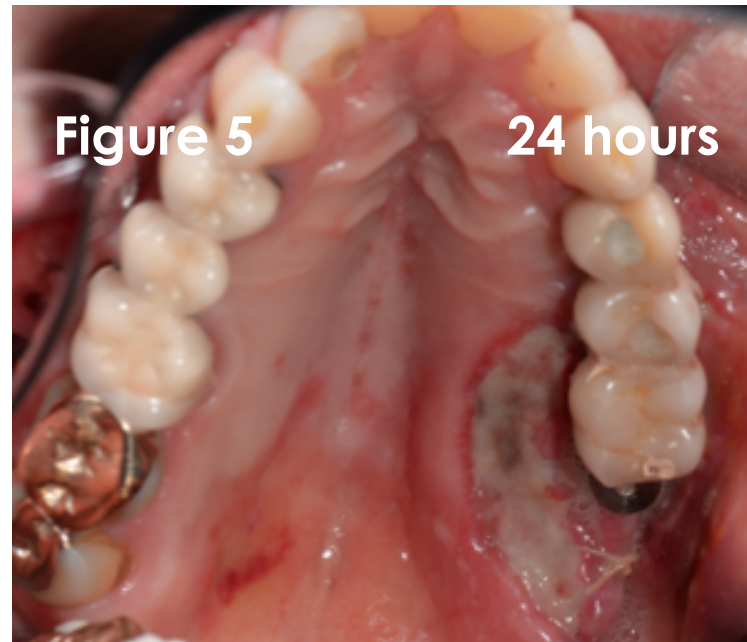
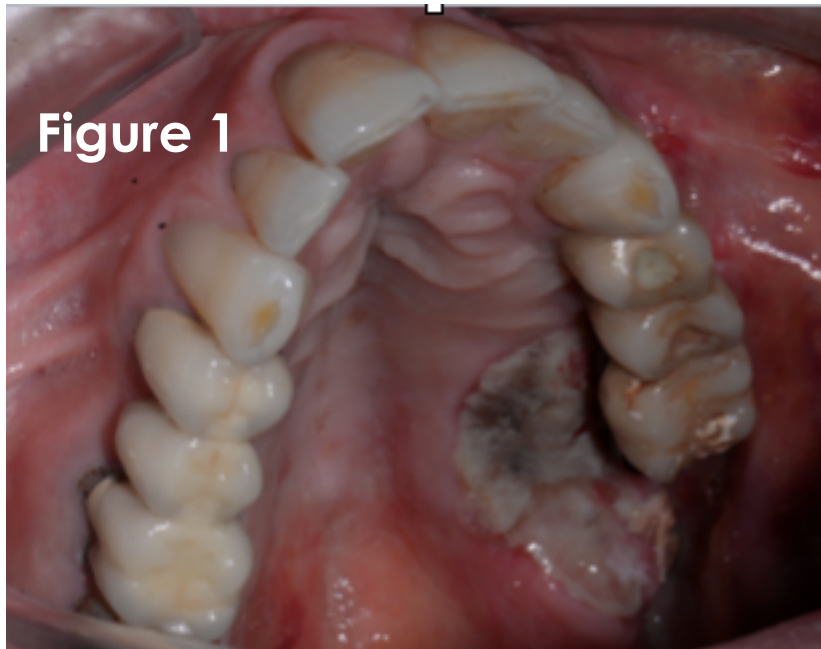
## BlueM, for the protection of injured periodontal tissue

An impression was made immediately to fabricate an appliance complete with reservoir for application of BlueM oral gel directly over the surgical site (Figure 2/3). The patient continued to wear the appliance on an ongoing basis, 24 hours.



BlueM, for the protection of injured periodontal tissue

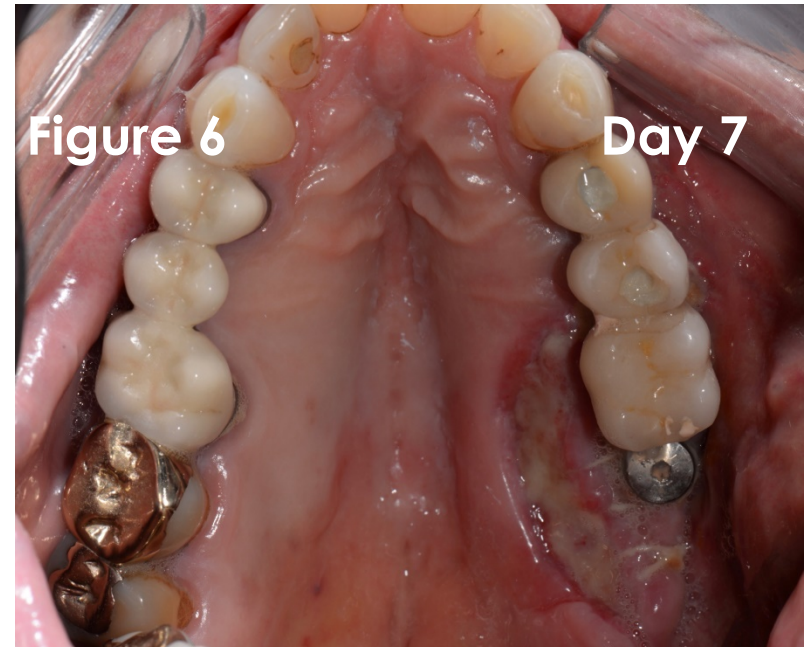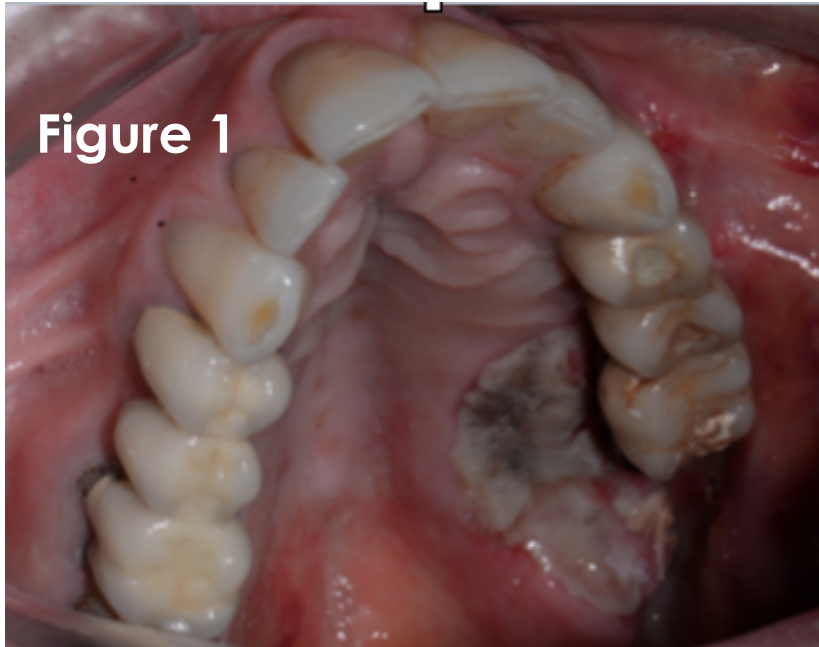
Result in only 24 hours!





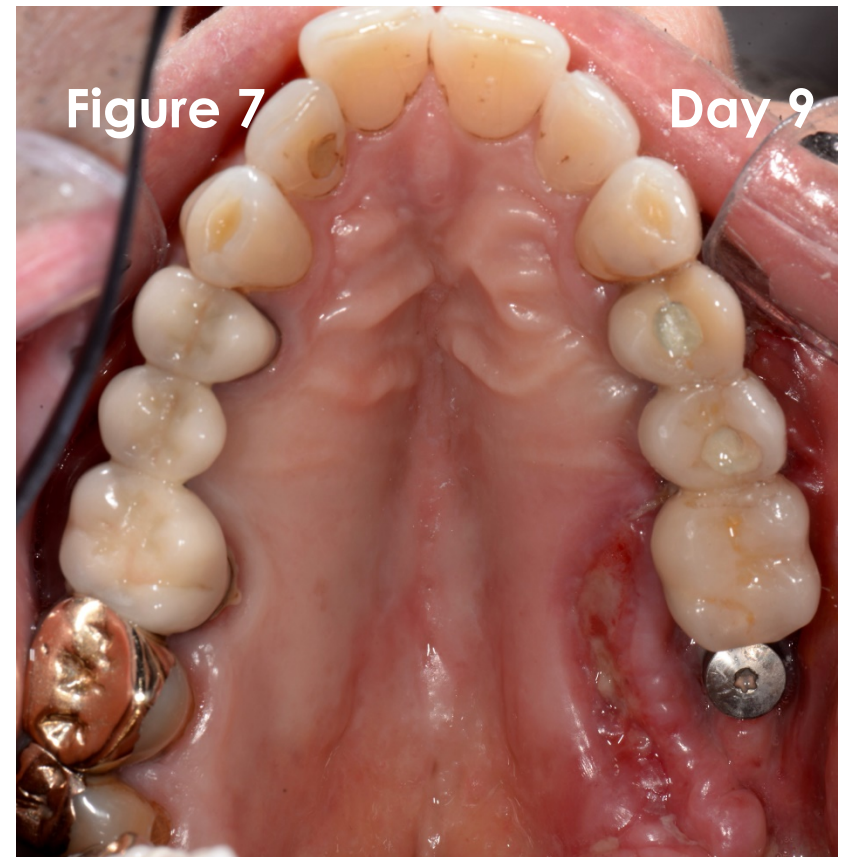
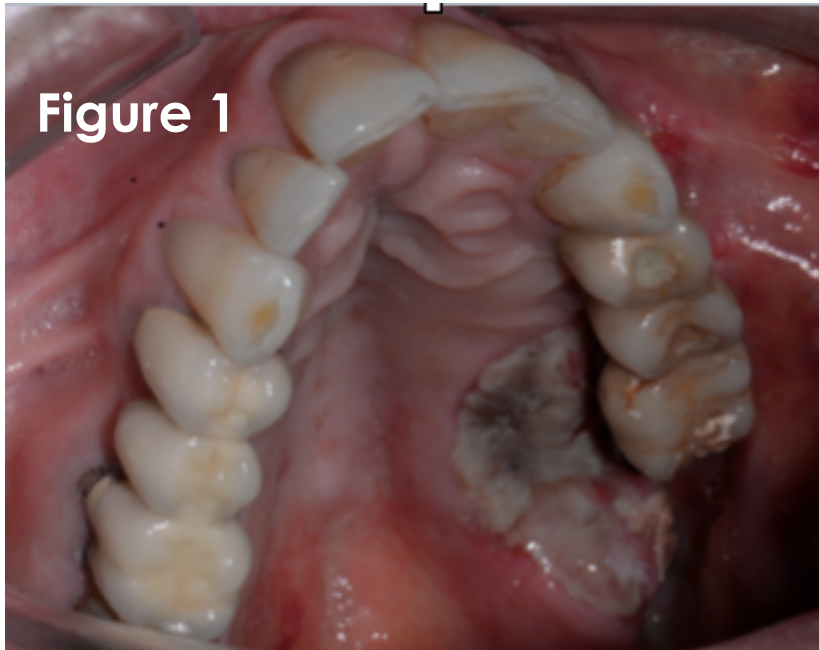
## BlueM, for the protection of injured periodontal tissue

At seven day post-op recall (Figure 6), the necrotizing deep ulcer showed further remarkable healing.



## BlueM, for the protection of injured periodontal tissue

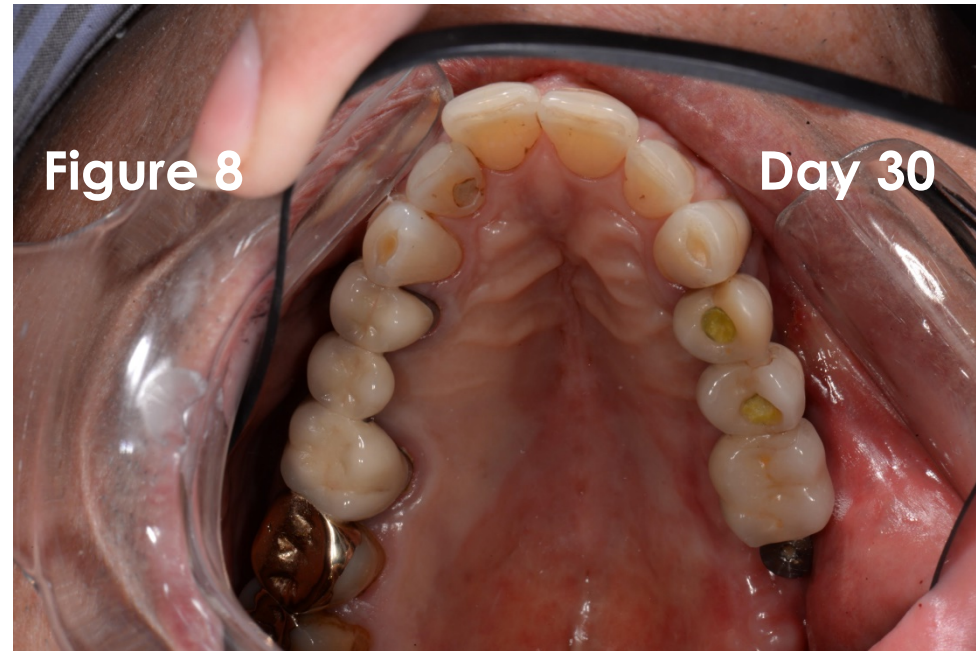
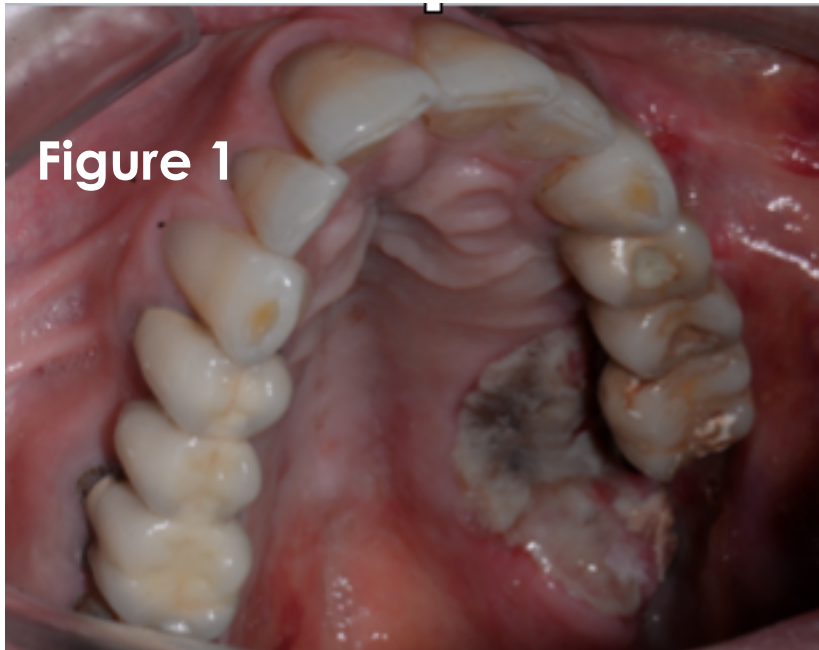
At nine day post-op recall (Figure 7), further improvement of the healing process.





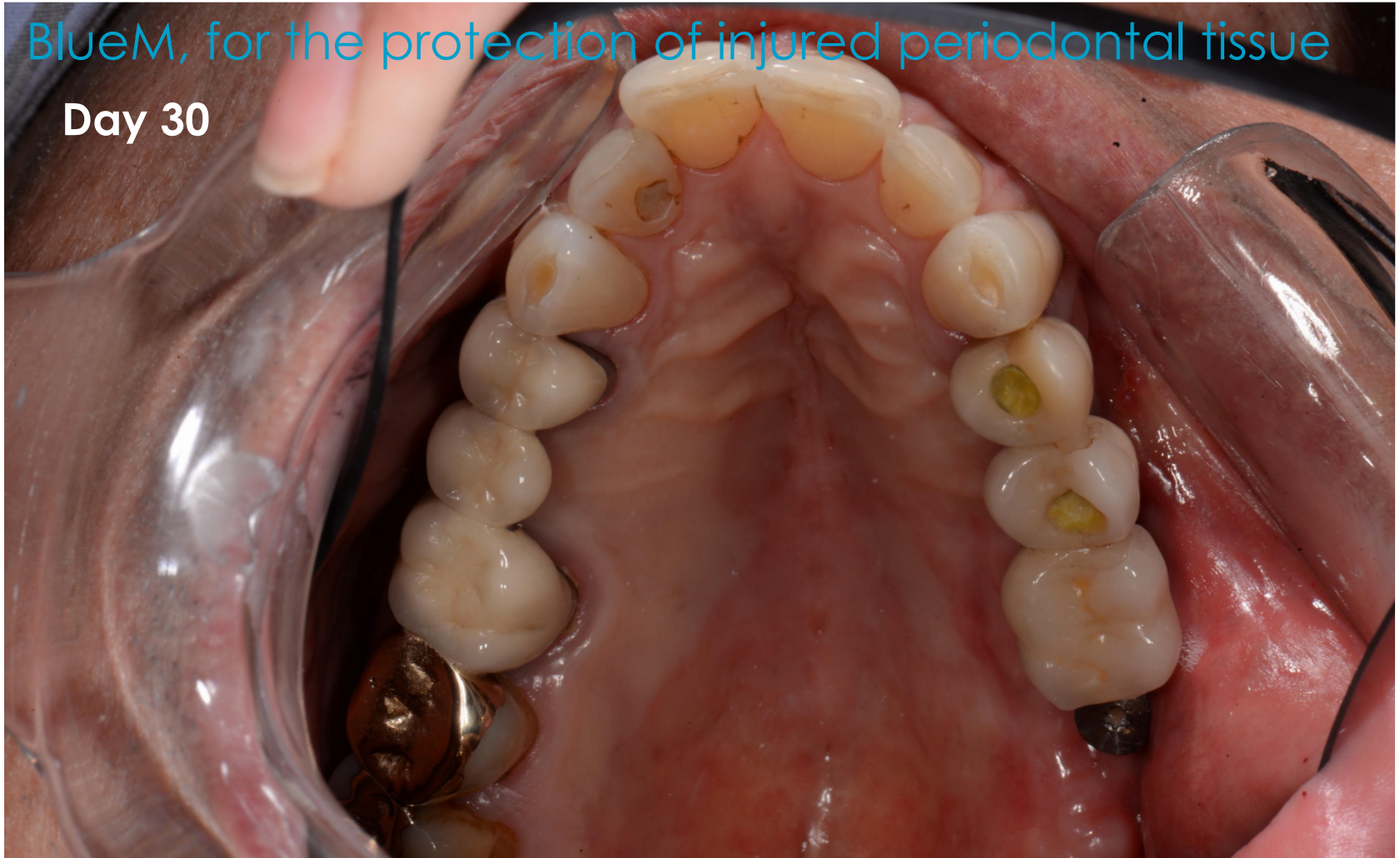
## BlueM, for the protection of injured periodontal tissue

At thirty day post-op recall (Figure 8), the acute necrotizing deep ulcer has completely healed.

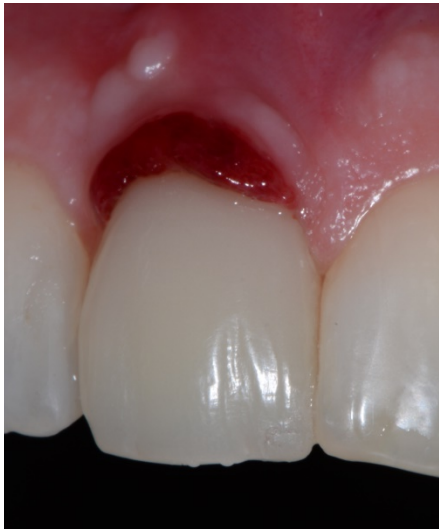

BlueM, for the protection of injured periodontal tissue

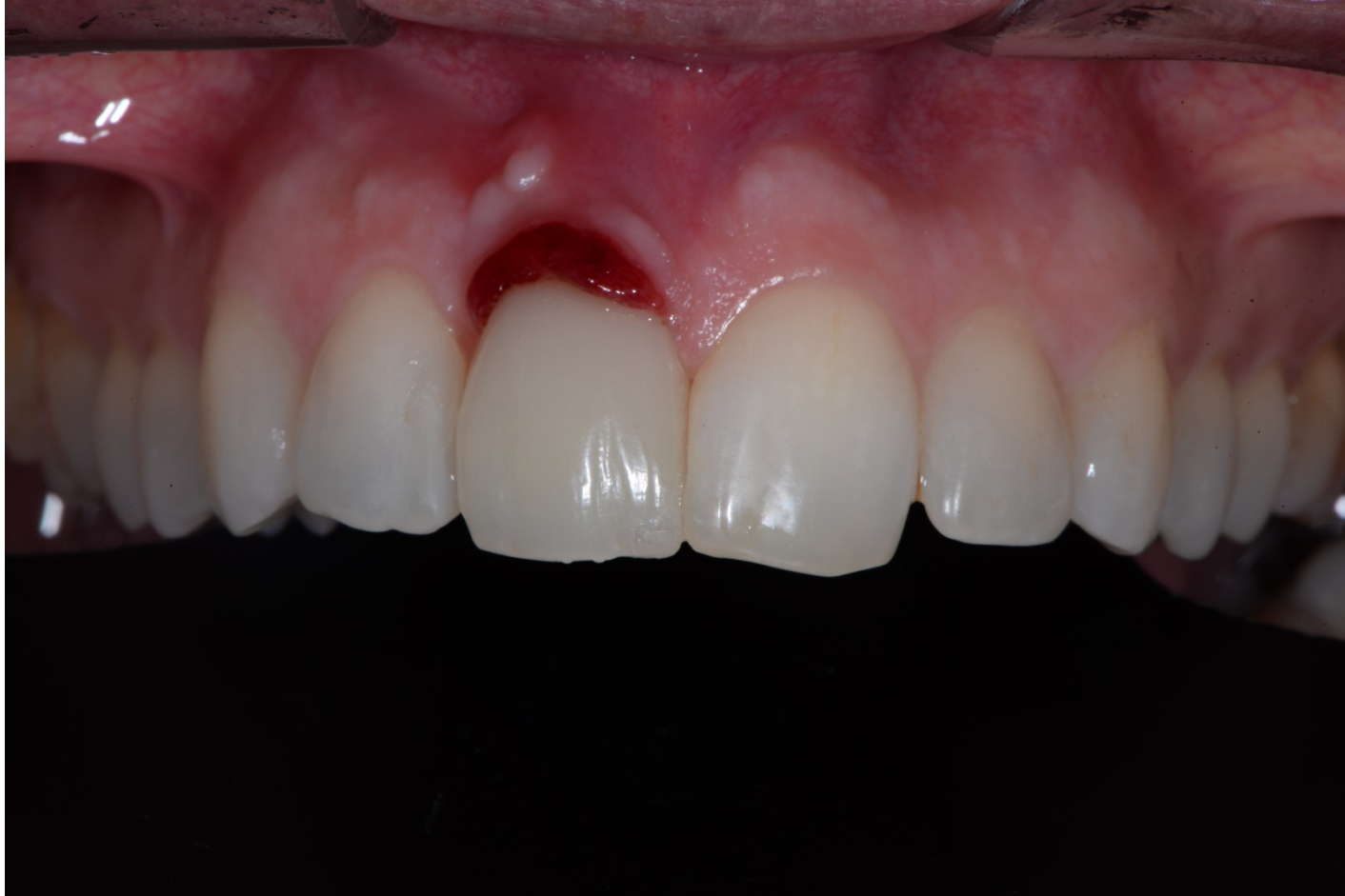**Day 30**



## BlueM, for the protection of injured periodontal tissue

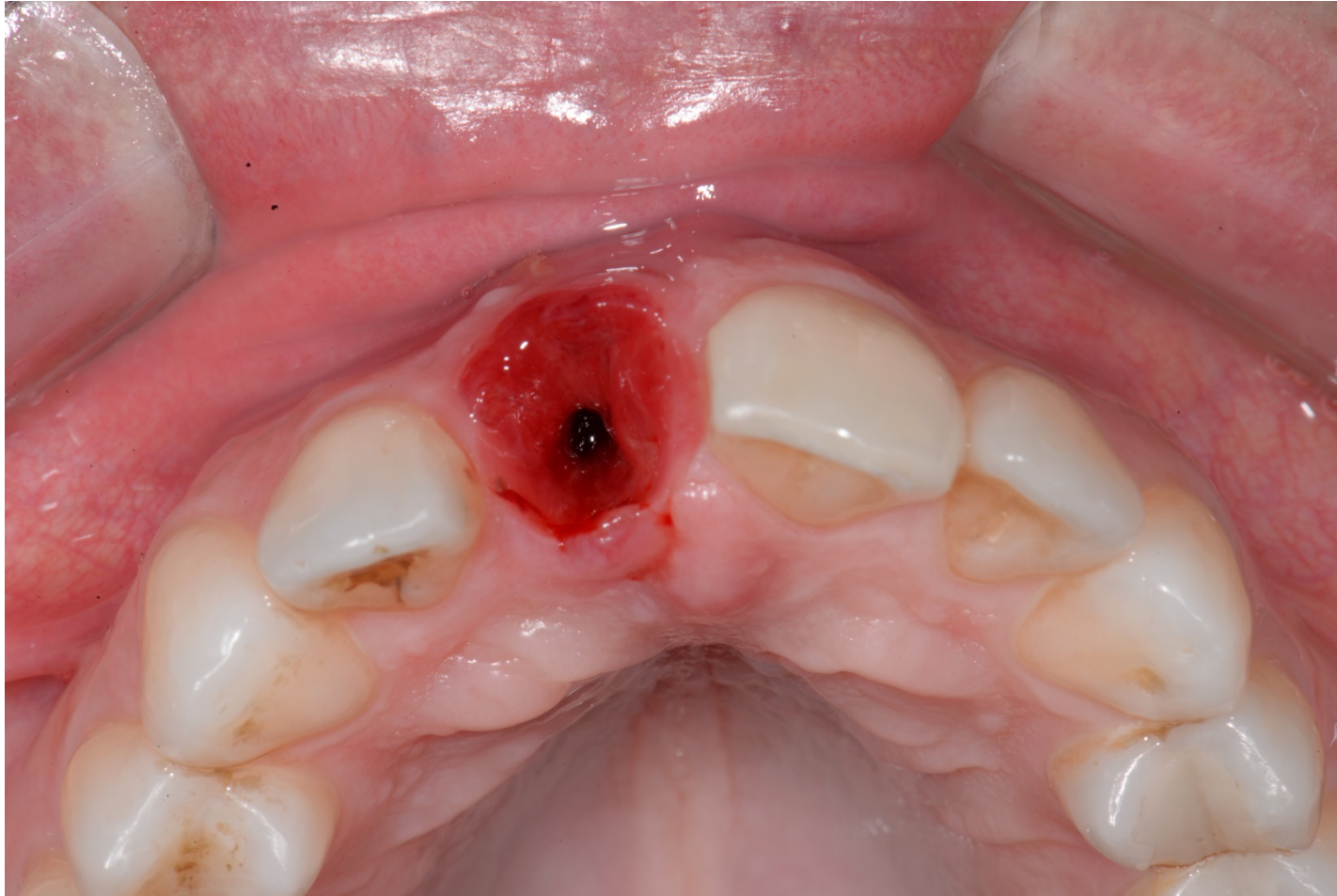


BlueM, for the protection of injured periodontal tissue





## BlueM, for the protection of injured periodontal tissue

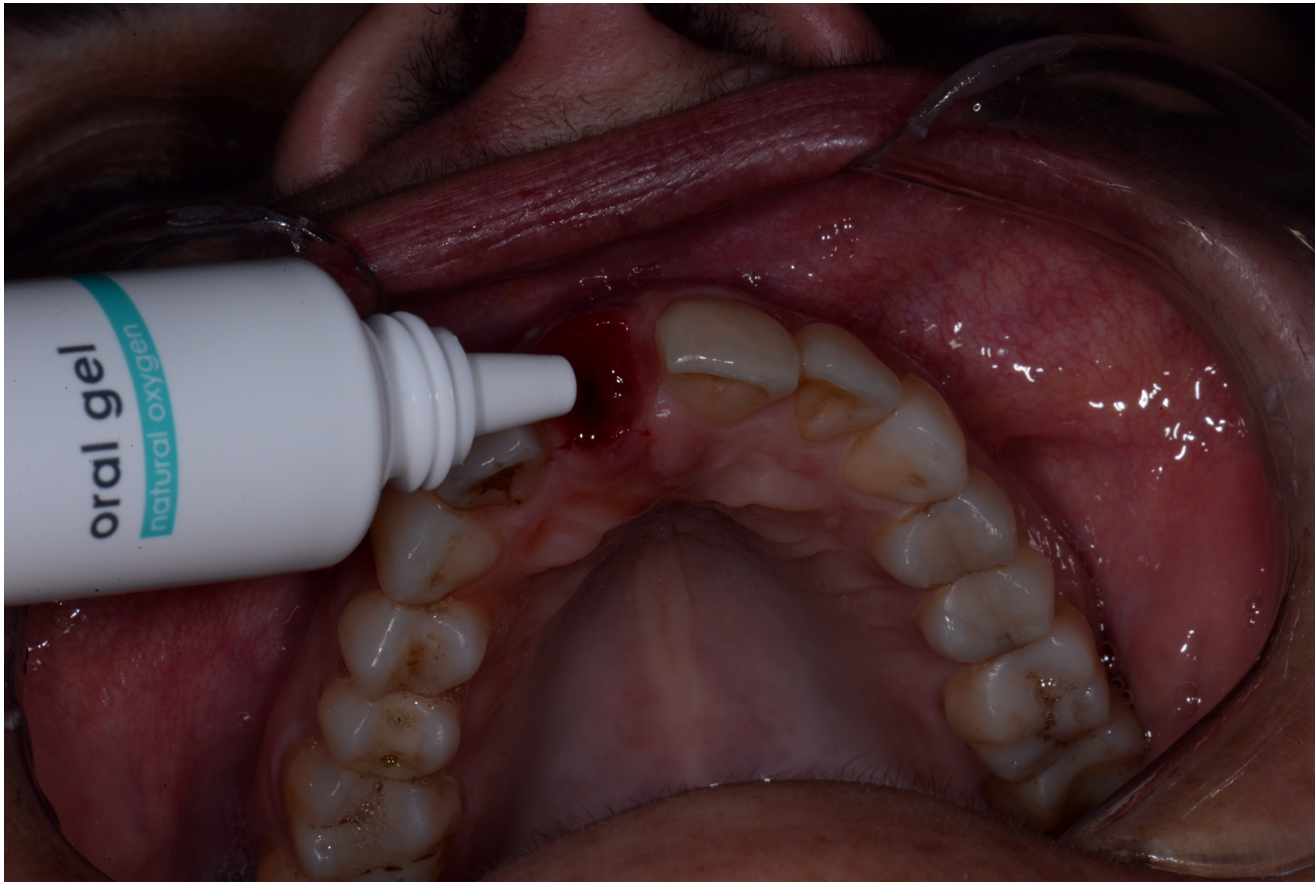




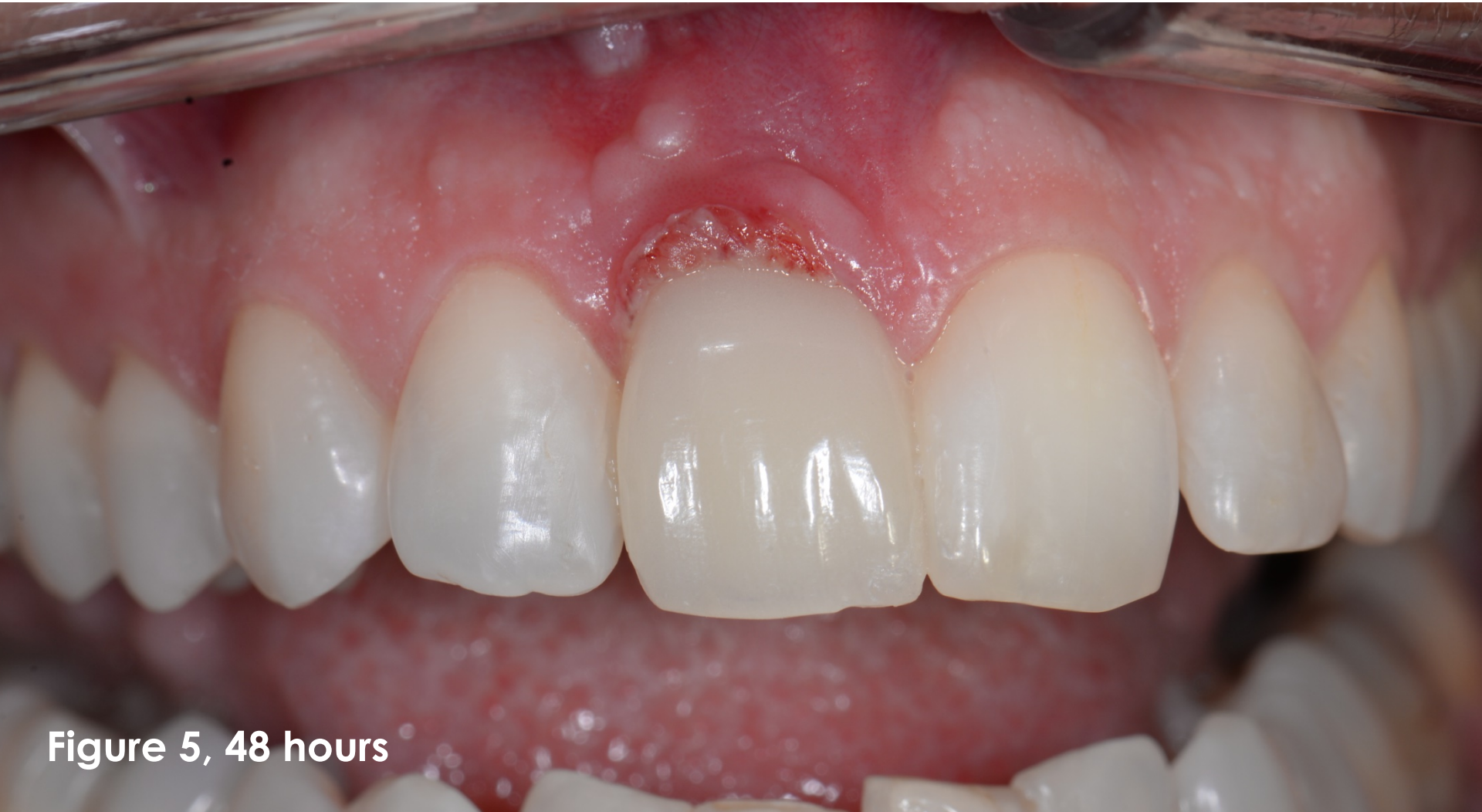## BlueM, for the protection of injured periodontal tissue

- Protocol followed:
  - \* 3x daily rinse for one minute with BlueM mouthwash.
  - \* 3x daily apply BlueM oral gel.

## BlueM, for the protection of injured periodontal tissue



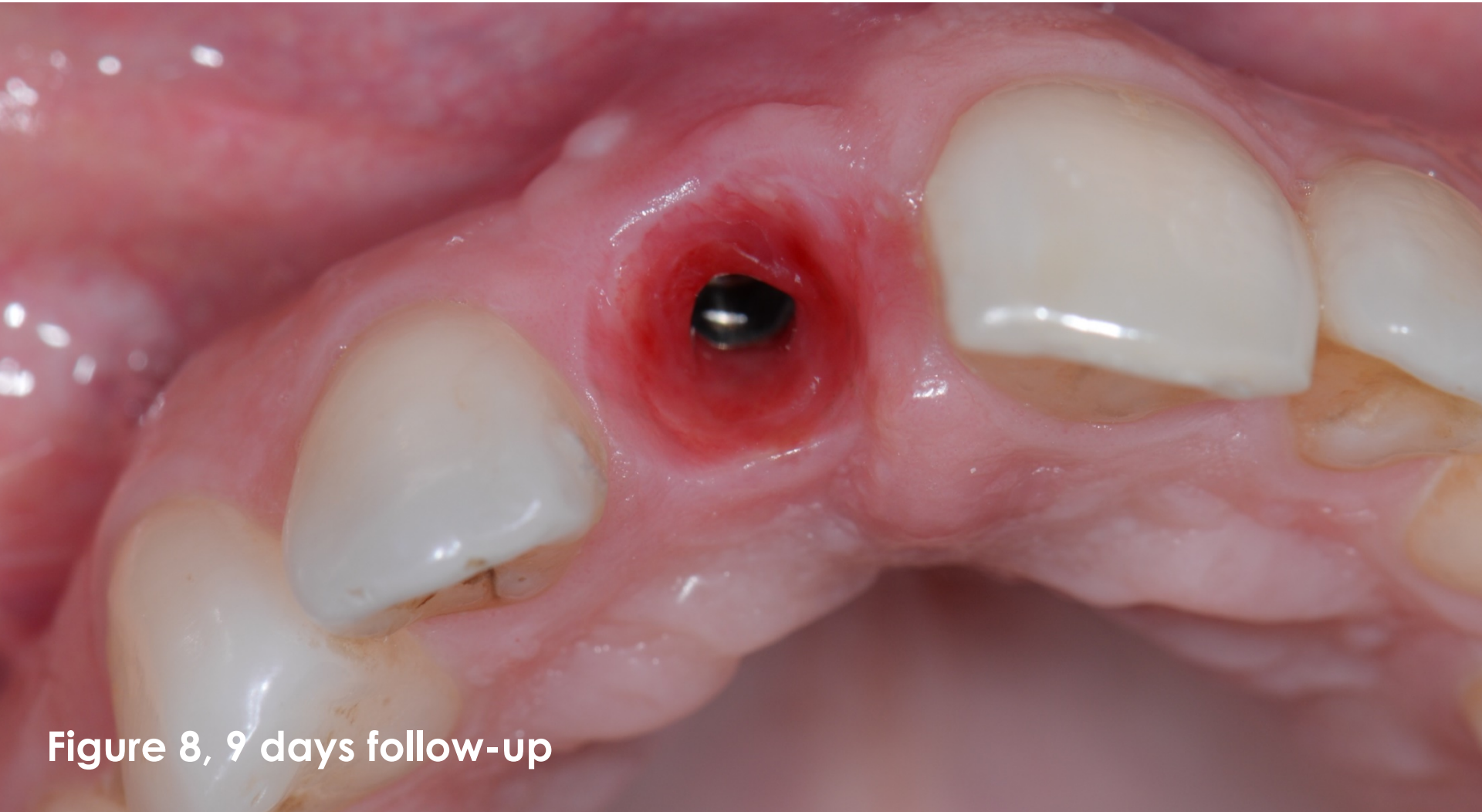
BlueM, for the protection of injured periodontal tissue



**Figure 5, 48 hours**

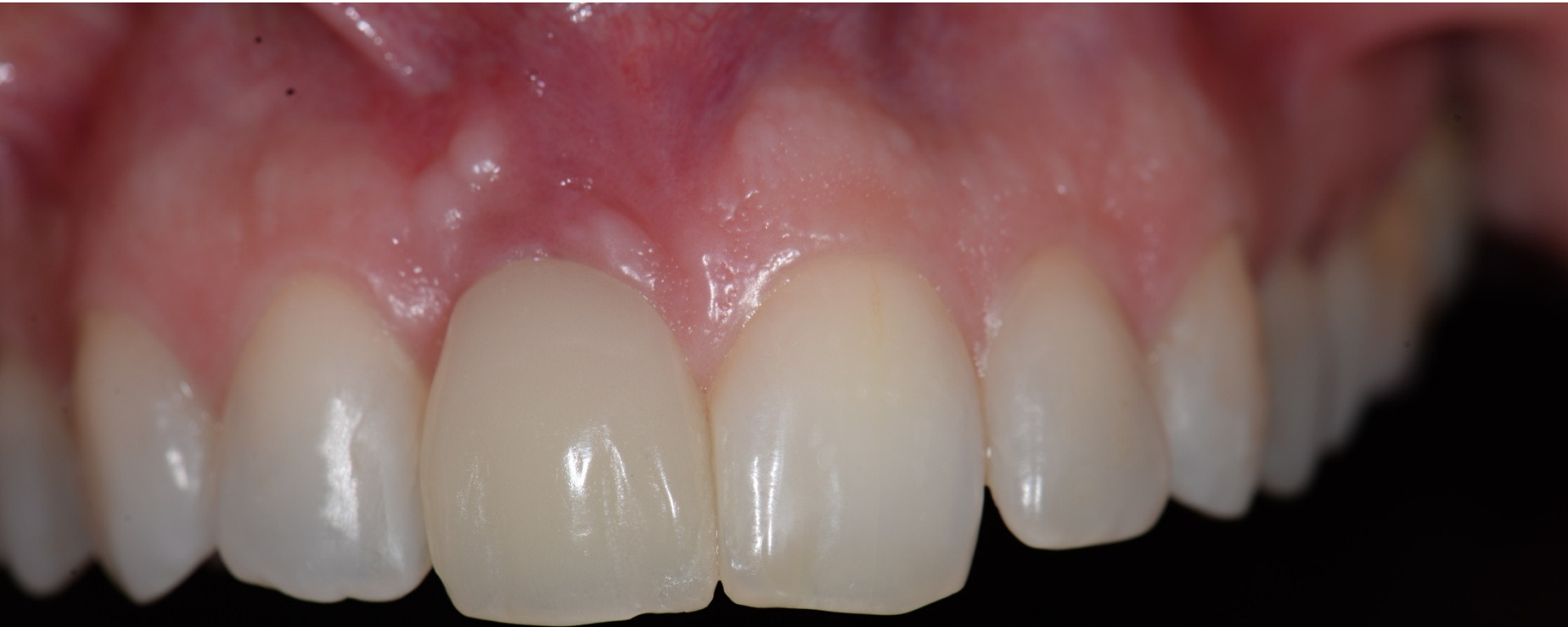

BlueM, for the protection of injured periodontal tissue



**Figure 8, 9 days follow-up**

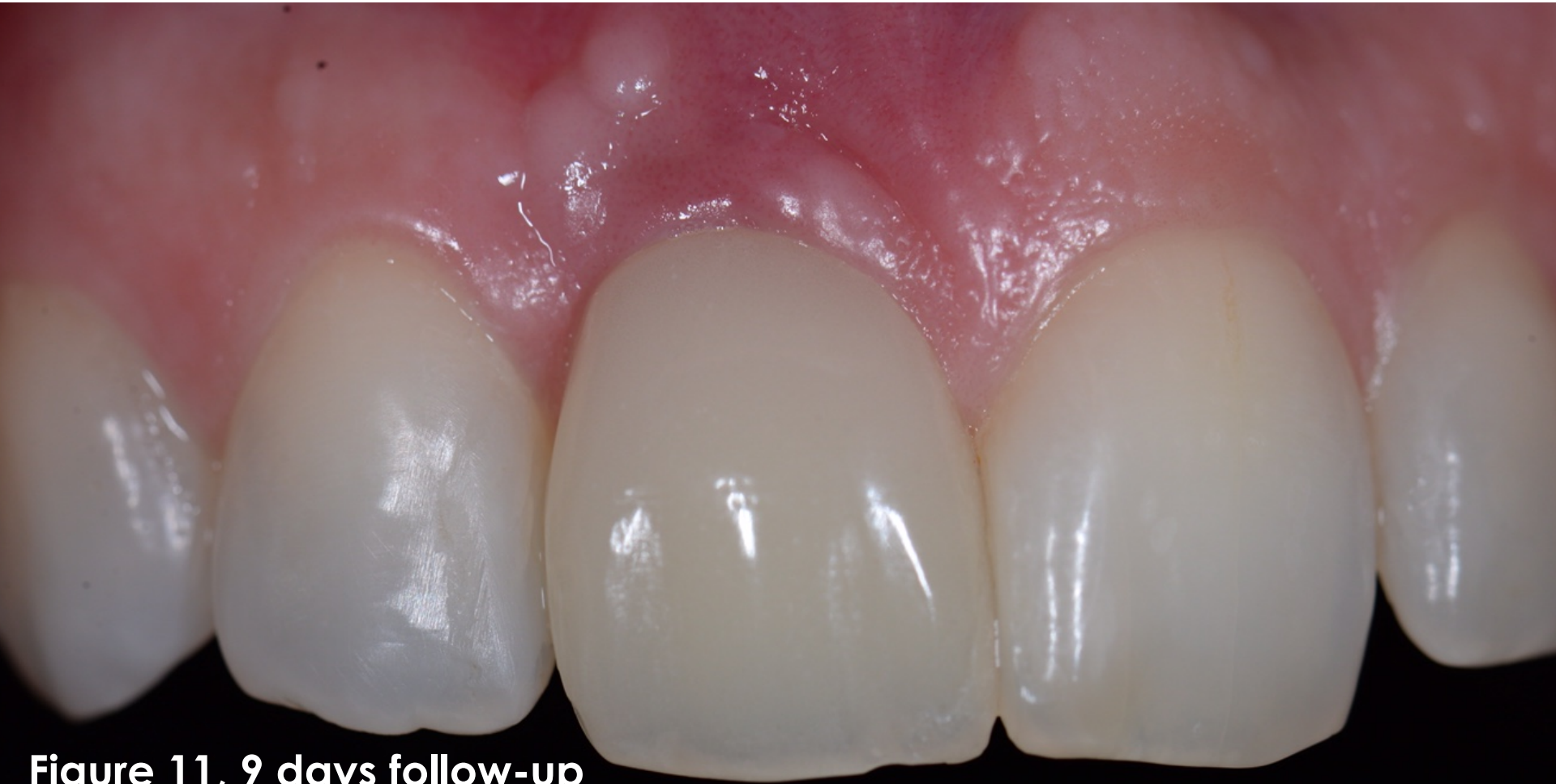BlueM, for the protection of injured periodontal tissue



**Figure 9, 9 days follow-up**

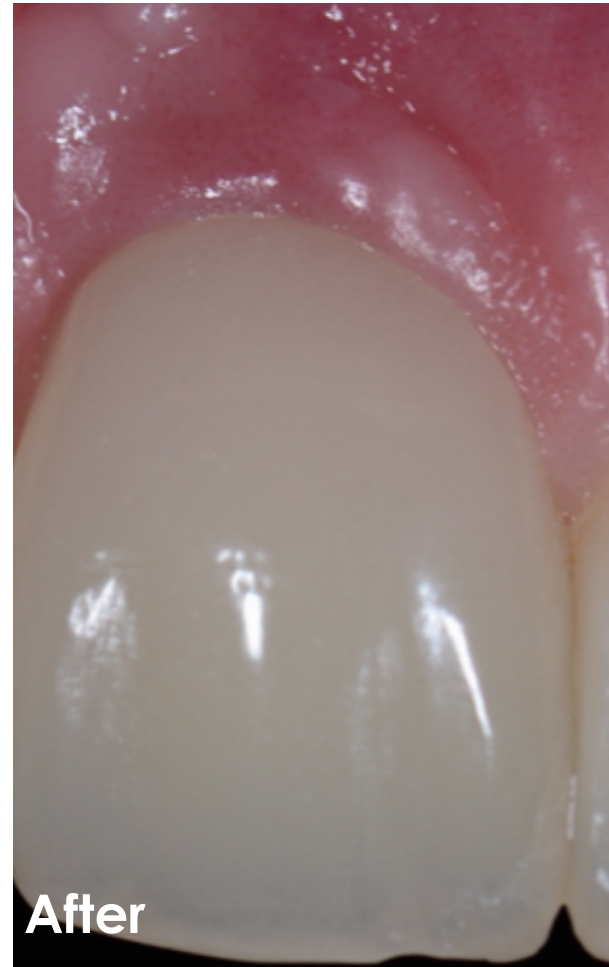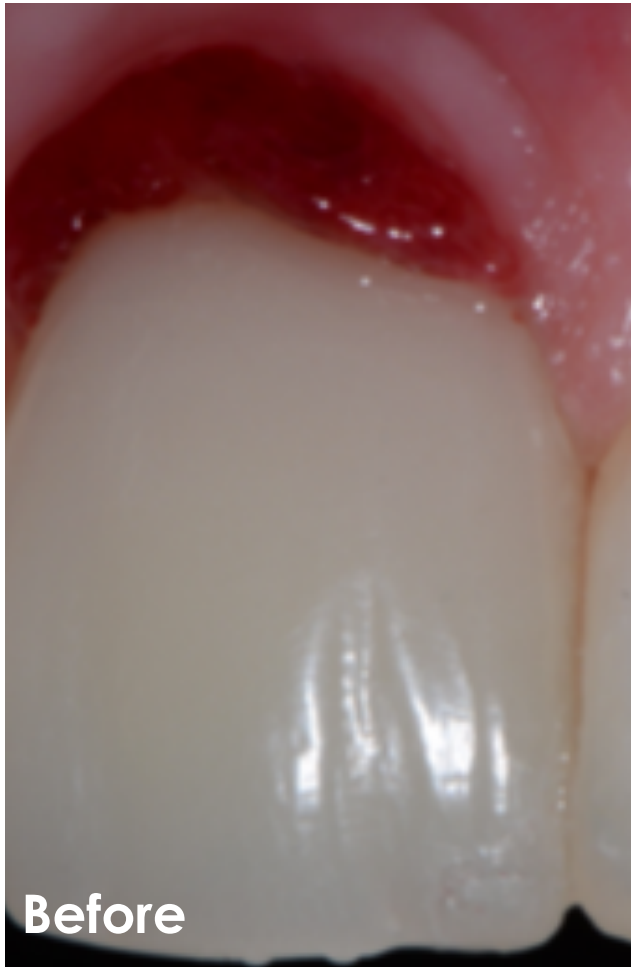


BlueM, for the protection of injured periodontal tissue

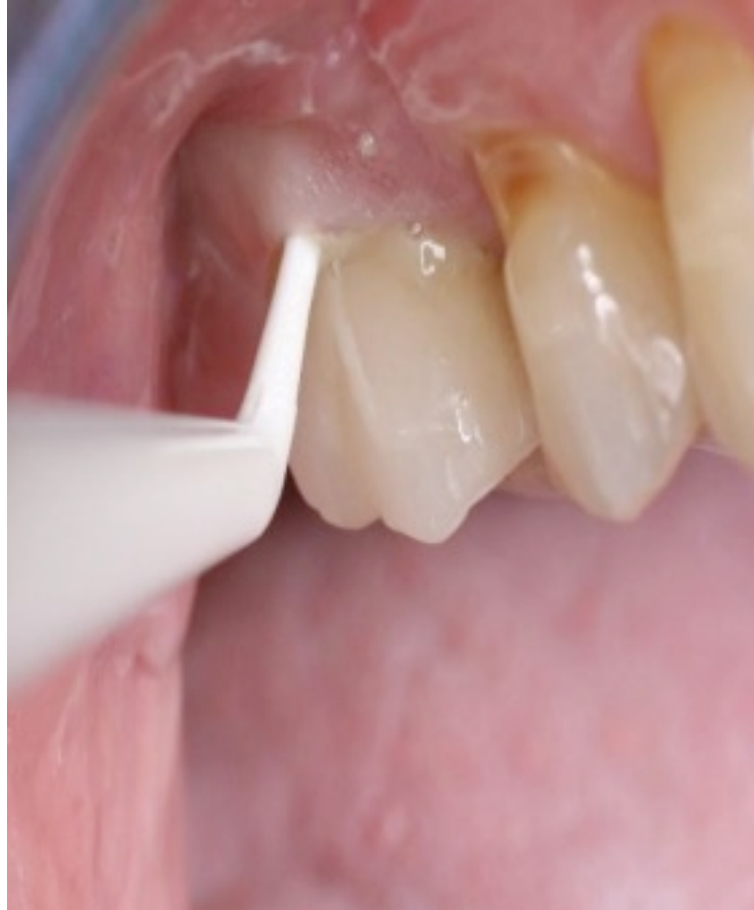

**Figure 11, 9 days follow-up**

BlueM, for the protection of injured periodontal tissue



# How to apply?



# Result after 14 days

