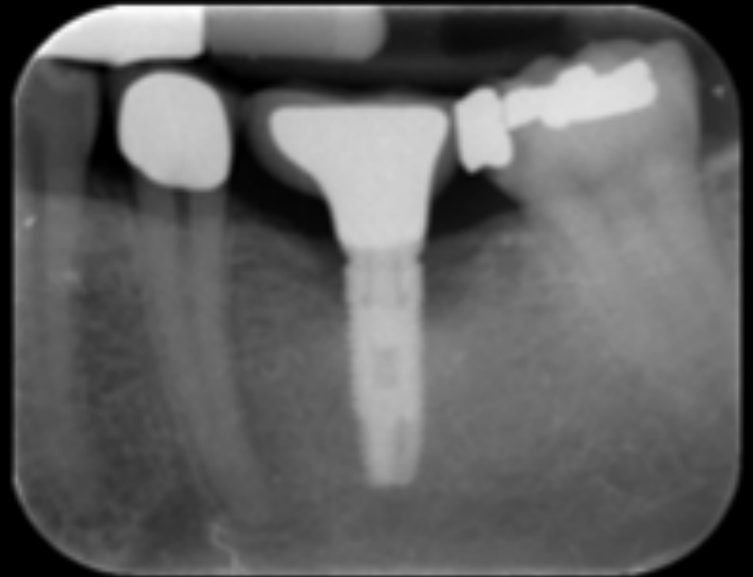


# Peri-implantitis

## Case 3

Before treatment:

- New patient male 39 years
- Peri-implantitis 36
- Circular bone-defect
- Pocket 9 mm

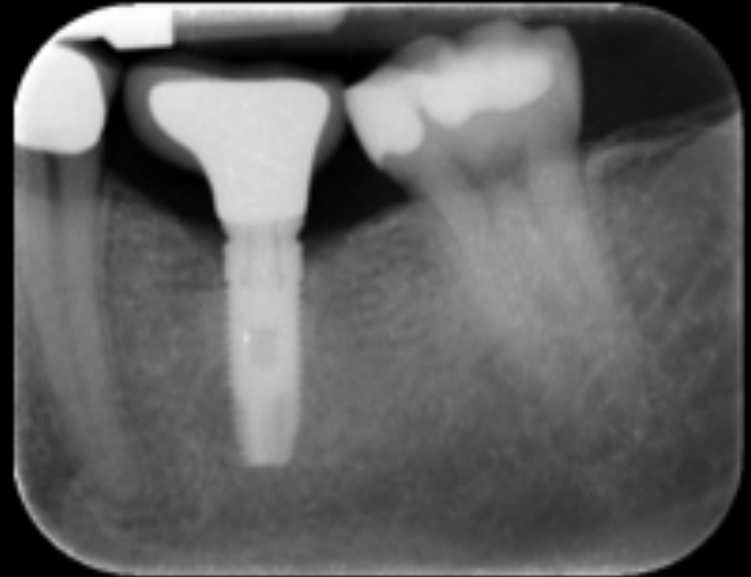


# Result after 1 year

## CASE 3

After 1 year of Active Oxygen:

- Circular bone regeneration
- Pocket reduction 9mm > 4 mm
- No bleeding



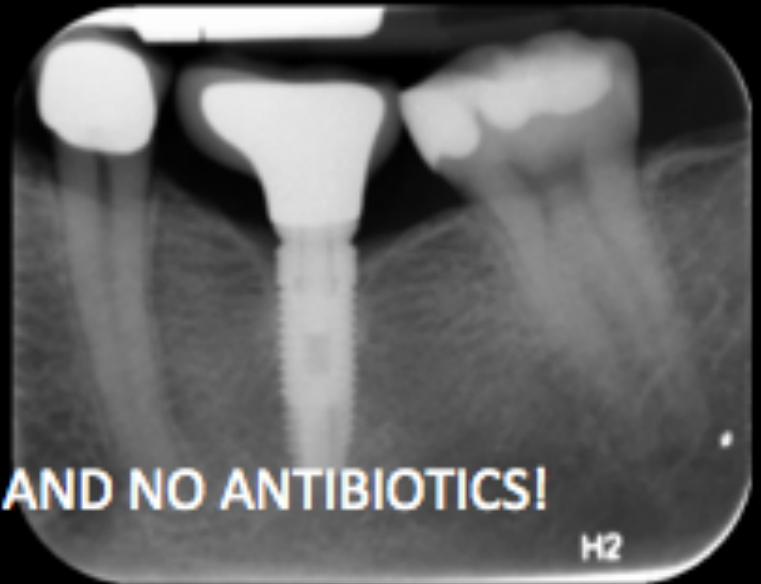# Check-up after 2 year

## CASE 3

After 2 years of Active Oxygen:

- Beautiful bone regeneration
- Pocket reduction 4mm > 3 mm

**NO SURGERY, NO CHLORHEXIDINE AND NO ANTIBIOTICS!**



# Result after 2 year

